

Submental Suction-Assisted Lipectomy without Platysmaplasty: Pushing the (Skin) Envelope to Avoid a Face Lift for Unsuitable Candidates

Joe M. Gryskiewicz, M.D.

Minneapolis, Minn.

Patients with submental fullness may not be candidates for a full or short-scar face lift because of medical contraindications, uncontrolled hypertension, a refractory nicotine habit, or anticoagulant medications, or patients may disqualify themselves because of cost, unavailable recovery time, or emotional resistance. Submental suction-assisted lipectomy has traditionally been reserved for younger patients. For older patients, suction-assisted lipectomy is typically used as an adjunct for face/neck lifts. This report describes experiences with suction-assisted lipectomy for older patients who were not face lift candidates, for the aforementioned reasons. The study goals were to better delineate the indications for submental suction-assisted lipectomy, as opposed to a face lift, and to obtain improved results with a less-invasive procedure. A 6-year study involving 132 patients (21 to 73 years of age), of whom 4.5 percent were men, was performed. Eighty-eight patients (67 percent), the primary focus of this study, were more than 40 years of age. Of those 88 patients, 24 patients (18 percent of the 132 patients in this series) were in their forties, 45 (34 percent) were in their fifties, 16 (12 percent) were in their sixties, and three (2.3 percent) were at least 70 years of age. The median follow-up time in this series was more than 1 year. The results were assessed with the five criteria for facial rejuvenation described by Ellenbogen and Karlin. All patients demonstrated improvement, with three to five of the Ellenbogen-Karlin neck rejuvenation criteria being met for each patient. All patients demonstrated an improved submandibular border, a more visible anterior sternocleidomastoid muscle border, and an improved neck angle (as determined with angle measurements). For many patients, all five of the Ellenbogen-Karlin criteria were met. A visible subhyoid depression and a visible thyroid cartilage bulge were the two criteria most often not met. A retrospective evaluation using Baker's preoperative classification of patient types for short-scar face lifts was performed. Results for patients more than 64 years of age (11 patients) were less satisfactory, often with redundant or crepe paper-like skin. Submental suction-assisted lipectomy, as opposed to a face lift, was observed to be a reasonable alternative for older patients who were unable or unwilling to undergo a face

lift. Localized fullness in the midline was observed to be the best predictor of a good outcome (even better than age or skin tone). A crepe paper appearance of the skin preoperatively was the best predictor of failure. The surgical anatomical features, technique, advantages, disadvantages, and principles are discussed. Complications and their treatment are addressed. It is concluded that submental suction-assisted lipectomy alone, without platysmaplasty, can be helpful for patients with submental fullness who are unsuitable candidates for a face lift and who accept the limitations of liposuction without platysmaplasty. Suction-assisted lipectomy can sufficiently contract and smooth the skin envelope for selected patients, with less consideration for age than previously proposed. (*Plast. Reconstr. Surg.* 112: 1393, 2003.)

When treating submental fullness, surgeons are faced with deciding between liposuction alone and a face lift.¹⁻⁵ Submental suction-assisted lipectomy is traditionally reserved for younger patients who possess good skin tone, to allow skin contraction and adherence.^{6,7} Patients in their late forties can rarely be afforded optimal results.⁸ For older patients, suction-assisted lipectomy is typically used as an adjunct for face/neck lifts.⁹⁻¹⁴ This study design assumes that consistently good results can be obtained for patients in their forties, fifties, and even early sixties.

Surgeons may refuse to perform a face lift because of common medical contraindications, such as blood-thinning medications, high blood pressure (>140/90 mmHg with treatment), or a refractory nicotine habit (Table I). In addition, some patients may refuse a face lift because of recovery time, cost, or an

From the University of Minnesota Academic Health Center, Cleft Palate and Craniofacial Clinics. Received for publication July 3, 2002; revised November 7, 2002.

DOI: 10.1097/01.PRS.0000083222.41089.DD

TABLE I
Criteria for Use of Suction-Assisted Lipectomy for
Unsuitable Face Lift Candidates

Medical Contraindications	Patient Refusal of Face Lift
High blood pressure ($>140/90$ mmHg with treatment)	Emotional aversion to magnitude of full or short-scar face lift
Smoking	Lengthy recovery
Anticoagulant medications	Cost prohibitive

emotional aversion to the magnitude of a full or even short-scar face lift. Perhaps reflecting a geographic phenomenon, many patients in my practice strongly desire to minimize facial rejuvenation treatment and avoid "such a big procedure" or "all that cutting."

What do you tell an older patient with submental fullness who is not a candidate for a face lift? You do not have to say no. The initial step is to discuss at length what limitations, if any, the patient is willing to accept.

ANATOMICAL FINDINGS AND DIAGNOSIS

During correction of submental fullness, the surgical goal is a balanced youthful facial profile.¹⁵⁻¹⁹ The general procedure for preoperative diagnosis is outlined in Table II. The criteria described by Ellenbogen and Karlin¹⁹ include the following: (1) a distinct inferior mandibular border, (2) a visible subhyoid depression (which helps the neck appear long and thin), (3) a visible thyroid cartilage bulge, (4) a visible sternocleidomastoid muscle border (the least important criterion), and (5) a sternocleidomastoid-submental line angle of 90 degrees or a cervicomental angle of 105 to 120 degrees (Fig. 1). Because the sternocleidomastoid-submental line angle in the youthful neck is approximately a

right angle, the angle can be evaluated visually, without measurements.

Skin

The surgeon should observe the patient for preoperative crepe paper appearance, which predicts the failure of suction-assisted lipectomy without a face lift. The surgeon should also observe the patient for multiple deep, permanent, horizontal and oblique creases and perform a snap-back test, pulling down caudally, to assess tone and elasticity. The surgeon should perform a pinch test, along the midline horizontally for laxity, to assess the risk of postoperative cervical ectropion.

Subcutaneous Midline Cervical Fat

The surgeon should assess the localization and amount of preplatysmal fat by palpation. Subplatysmal fat is filled with connective tissue and, unlike softer preplatysmal fat, is very fibrous. The surgeon may suspect subplatysmal fat preoperatively if the subcutaneous tissue in the midline feels very firm, but the diagnosis can be confirmed only with direct exploration.

Superficial Musculoaponeurotic System

The following questions should be addressed.²⁰ Is there loss of support? Does upward tension on the lower face help support lax tissue? Is ptosis of the upper neck present? Is the platysma muscle relaxed?

Platysma

The surgeon should observe the patient for cervical fullness without bands, visible bands without animation, or medial platysmal bands that are active with natural animation.

TABLE II
Preoperative Diagnosis

Place patient in a well-lit area
Perform sausage test; finding longitudinal midline fullness with palpation or squeezing of the cervical midline is the best indication for proceeding with lipectomy
Note that localized fullness in the midline is the best predictor of a good outcome (even better than age or skin tone)
Palpate subcutaneous fullness in the neck with tensing of the platysma muscle, to distinguish between fat and thick muscle
Observe quantity and location of subcutaneous fat
Observe preoperative crepe paper appearance, the best predictor of failure
Perform pinch test for subcutaneous thickness of ≥ 1.5 -2 cm
Have patient turn side to side
Have patient move head up and down
Carefully note asymmetries
Observe submaxillary gland fullness
Note multiple deep, permanent, horizontal and oblique creases
Perform snap-back test; for tone and elasticity
Perform pinch test for laxity; avoid cervical ectropion

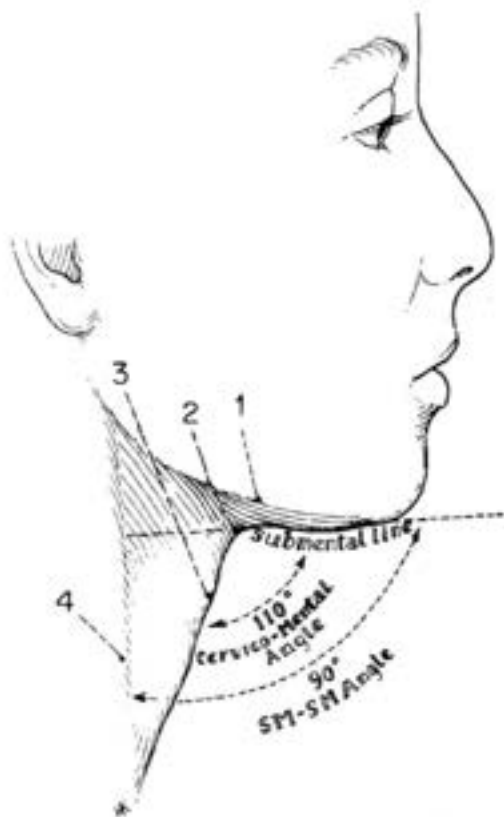


FIG. 1. Criteria for a youthful neck, including a distinct inferior mandibular border (1), a visible subhyoid depression (2), a visible thyroid cartilage bulge (3), a visible anterior sternocleidomastoid muscle border (4), a submental-sternocleidomastoid line (SM-SM) angle of 90 degrees, or a cervicomental angle of 105 to 120 degrees (5). (Reprinted from Ellenbogen, R., and Karlin, J. V. Visual criteria for success in restoring the youthful neck. *Plast. Reconstr. Surg.* 66: 826, 1980.)

Hyoid-Thyroid Complex Location

A low position hinders achievement of optimal results.²¹⁻²³ The surgeon should establish the position with gentle pressure, with a cotton swab, at the cervicomental angle.²⁴

Mandibular Length and Contour Contributions to Aging

The surgeon should draw a line down from the lower lip.²⁰ For women, the mentum should be on or slightly behind this line. For men, the mentum should be on or anterior to this line.

PATIENTS AND METHODS

Between January of 1994 and January of 2000, 132 patients underwent submental suction-assisted lipectomy in my practice. Follow-up periods were more than 1 year for all patients. Patient ages ranged from 21 to 73

years, with the average age being 48.1 years. This study focused on 88 patients (67 percent) who were more than 40 years of age. Of those 88 patients, 24 (18 percent of the 132 patients in this series) were in their forties, 45 (34 percent) were in their fifties, 16 (12 percent) were in their sixties, and three (2.3 percent) were at least 70 years of age. Older patients who were unsuitable for or unwilling to undergo a face lift or whose goal was a more limited result were afforded submental suction-assisted lipectomy. I depended heavily on preoperative and postoperative photographs during meticulous discussions of the alternatives for cervical rejuvenation, and each patient and I jointly reached a decision. During the last 2 years of the study, ultrasound-assisted lipectomy was used to induce skin contracture for male patients, because of their thicker skin. Concomitant chin augmentation was performed for five patients (4 percent). The results were assessed with the Ellenbogen-Karlin criteria for facial rejuvenation, as well as measurements of changes in sternocleidomastoid-submental line angles. Retrospective evaluation by using Baker's preoperative classification of patient types for short-scar face lifts was performed.

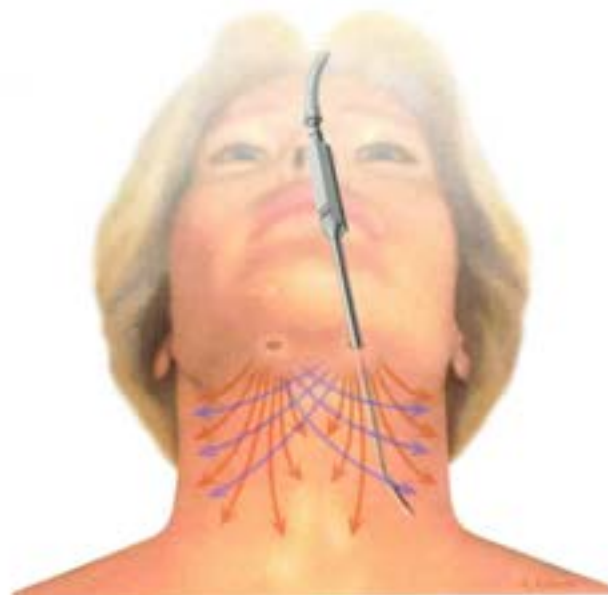


FIG. 2. Submental suction-assisted lipectomy entry sites. The use of two submental entry sites avoids residual fullness areas lateral to the incision, which can occur with a single midline entry site. Also, the use of two submental entry sites allows a criss-cross pattern and can avoid intralobular incisions.

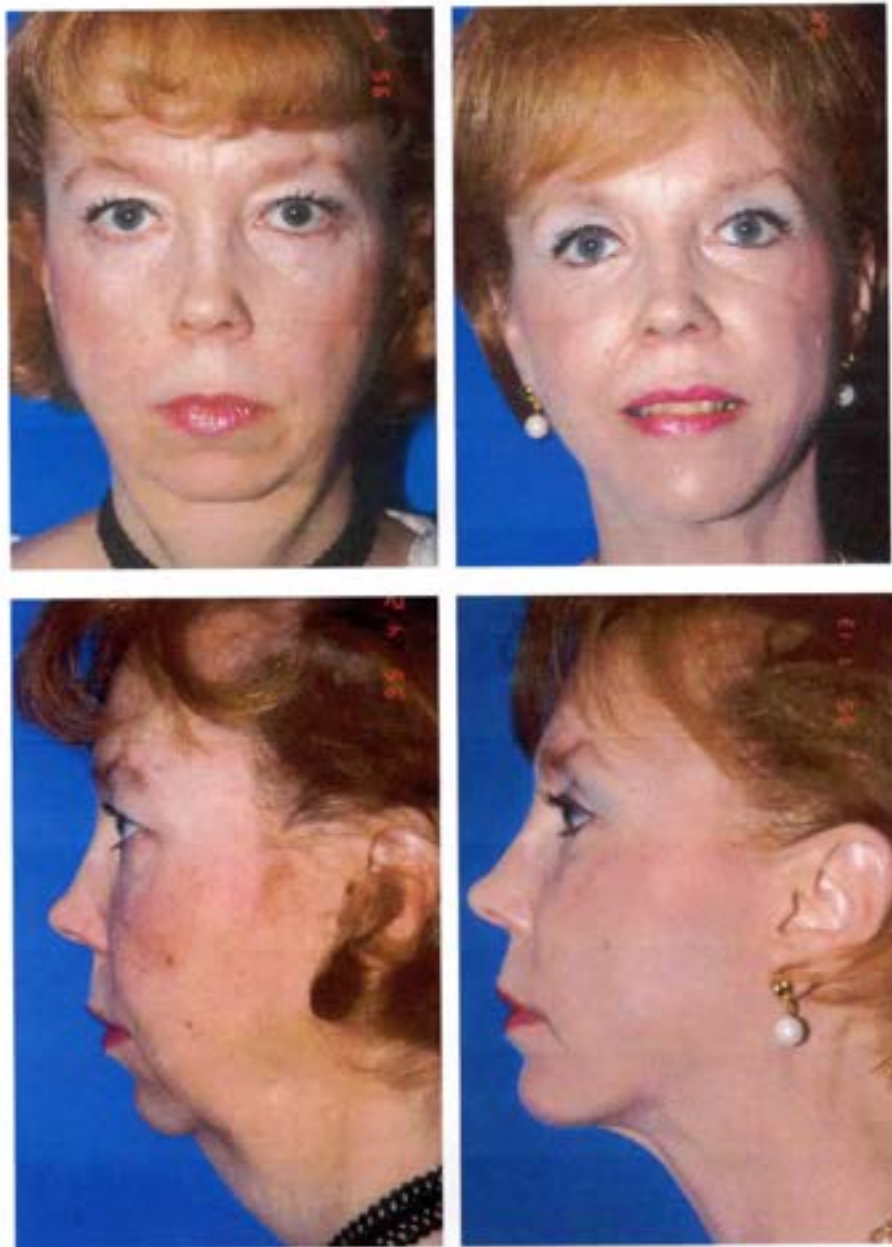

FIG. 3. Case 1. (Left) This 53-year-old female patient had juvenile-onset, brittle, insulin-dependent diabetes mellitus and a refractory nicotine habit. She strongly desired improvement, but I refused to perform a face lift. The patient exhibited localized fullness, with no crepe paper appearance to her skin. (Right) Two months after suction-assisted lipectomy, chin implant placement, and upper lid blepharoplasty, Ellenbogen-Karlin criteria 1, 2, 4, and 5 were met. Criterion 3 (visible thyroid cartilage bulge) was not met.

Surgical Technique

Preoperative marking was performed with the patient in the sitting position. Pinch tests were used to draw an exact topographic map. Asymmetries in fat distribution and submaxillary gland fullness were carefully noted.¹ The head was turned side to side and up and down. Two small incisions were marked approxi-

mately 1 cm from the midline on each side, near the submental crease. The use of two submental entry sites avoids residual fullness areas lateral to the incision, which can occur with a single midline entry site. The patient verified the surgical marking while looking in a mirror.

Suction-assisted lipectomy was performed

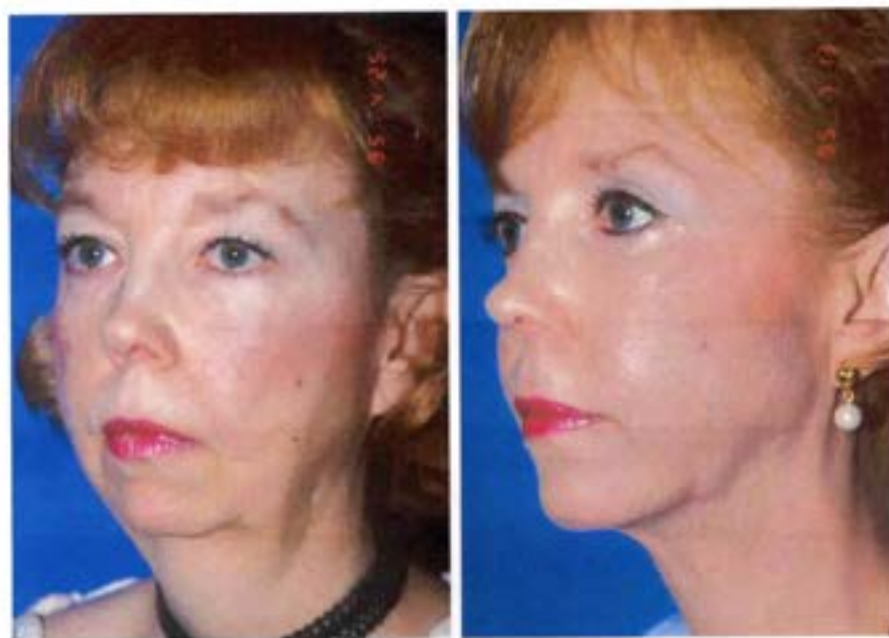

FIG. 4. Case 1. (Left) Before treatment. (Right) Two months after treatment.

with intravenous sedation or general anesthesia. I preferred intravenous sedation, if possible, to avoid the use of a laryngeal mask airway or endotracheal tube, because the tube inhibited access to the cervical midline and could cause traction asymmetry. The surgical area was infiltrated with 0.5 percent lidocaine with 1:200,000 epinephrine. The injected tissue was massaged for a few minutes, to facilitate dispersion of the injected fluid and the definition of landmarks. Two separate incisions allowed suctioning from as many angles as possible, in a criss-cross pattern (Fig. 2). Earlobe incisions were seldom necessary, unless they were used for sculpting of the jawline and buccal areas. Infralobular incisions required undermining to the anterior border of the sternocleidomastoid muscle, to avoid subplatysmal entry and marginal mandibular nerve injury.

Dry tunneling (repetitive motion without suction) at the start of the procedure was found to be helpful. A small cannula was used to establish the correct plane and to decrease resistance. Suction-assisted lipectomy was initiated in the midline, with a short 3-mm or 4-mm mushroom cannula. This flanged cannula design proved to be helpful for midline, sausage-shaped fullness, because the sharper edges of the mushroom cannula undermined the skin, facilitating retraction. This cannula released the dermal attachments of the platysma muscle, which resulted in better definition and

helped avoid a wrinkled appearance of the skin. Suctioning to the medial border of the sternocleidomastoid muscle was performed with a 2-mm or 3-mm cannula. Finally, cross-tunneling of the same area with a 1.8-mm to 2-mm cannula through both incisions created a smooth contour. The cannula was moved to a new area with each pass, to avoid ridging. Intraoperative judgment was used to cautiously suction immediately below the dermis.^{24,25}

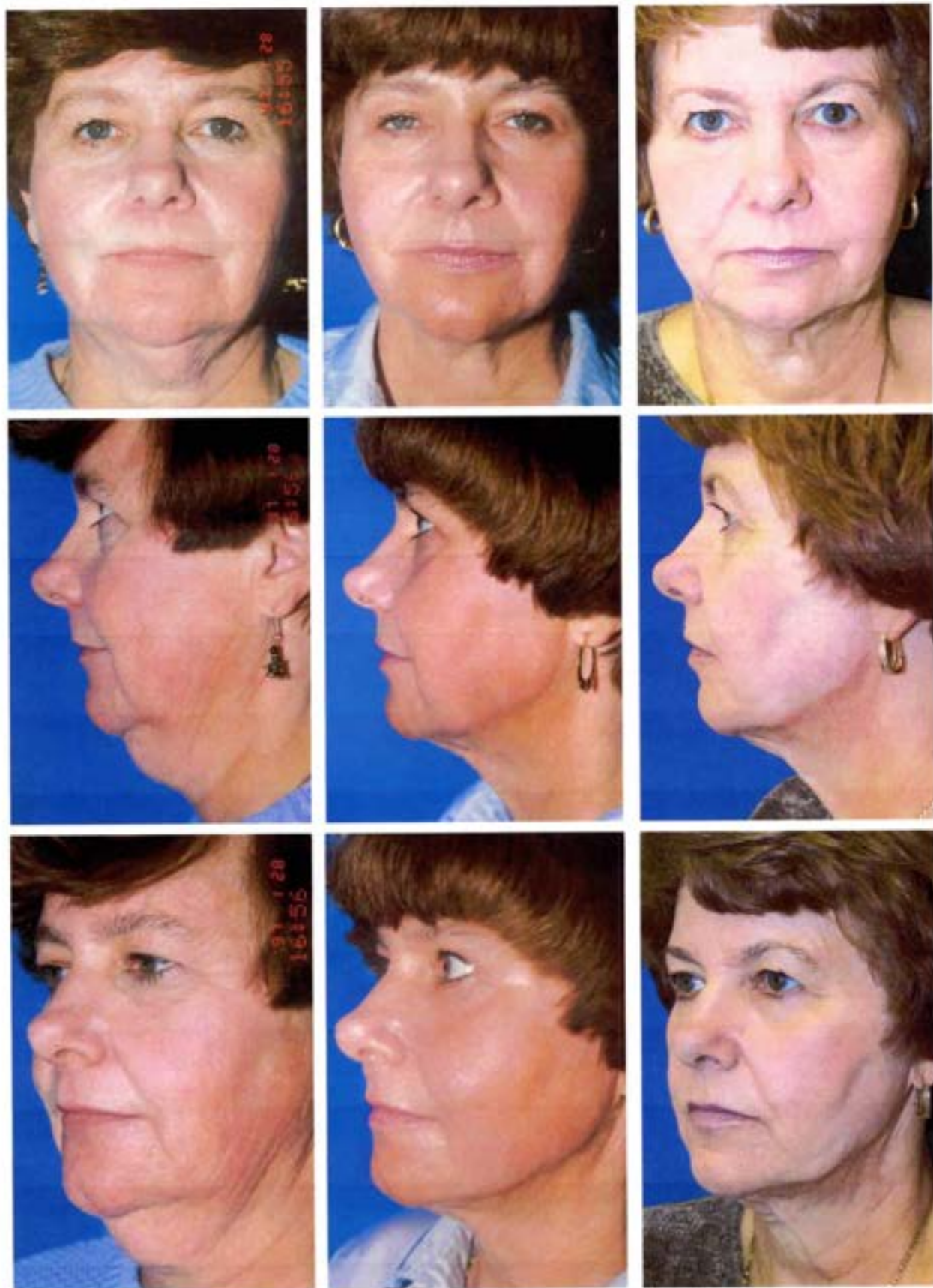Because the jowls are unforgiving, the surgical technique was slightly altered. Hand aspiration with a syringe, similar to fat harvesting for lipotransfer, worked well in my experience. Dry tunneling alone, without suction, also im-

TABLE III

Complications of Submental Suction-Assisted Lipectomy

Complication	No. of Patients
Touch-up liposuction required	13 (10%)
Secondary procedure overall, excluding normal touch-up rate	7 (5.5%)*
Demonstrated exposure of occult platysma bands	10 (7.6%)
Subsequent microlipoinfiltration for irregularities in jawline and cervical midline	4 (3%)
Subsequent face/neck lift unrelated to volume removed	3 (2.3%)
Skin adherence to underlying muscle, all localized to the cervical midline	3 (2.3%)
Lipectomy exposure of a ptotic submandibular gland, with no subsequent treatment	2 (1.5%)
Over-removal of cervical fat, causing cobra-like depression	0 (0%)

* Acceptable in my practice.



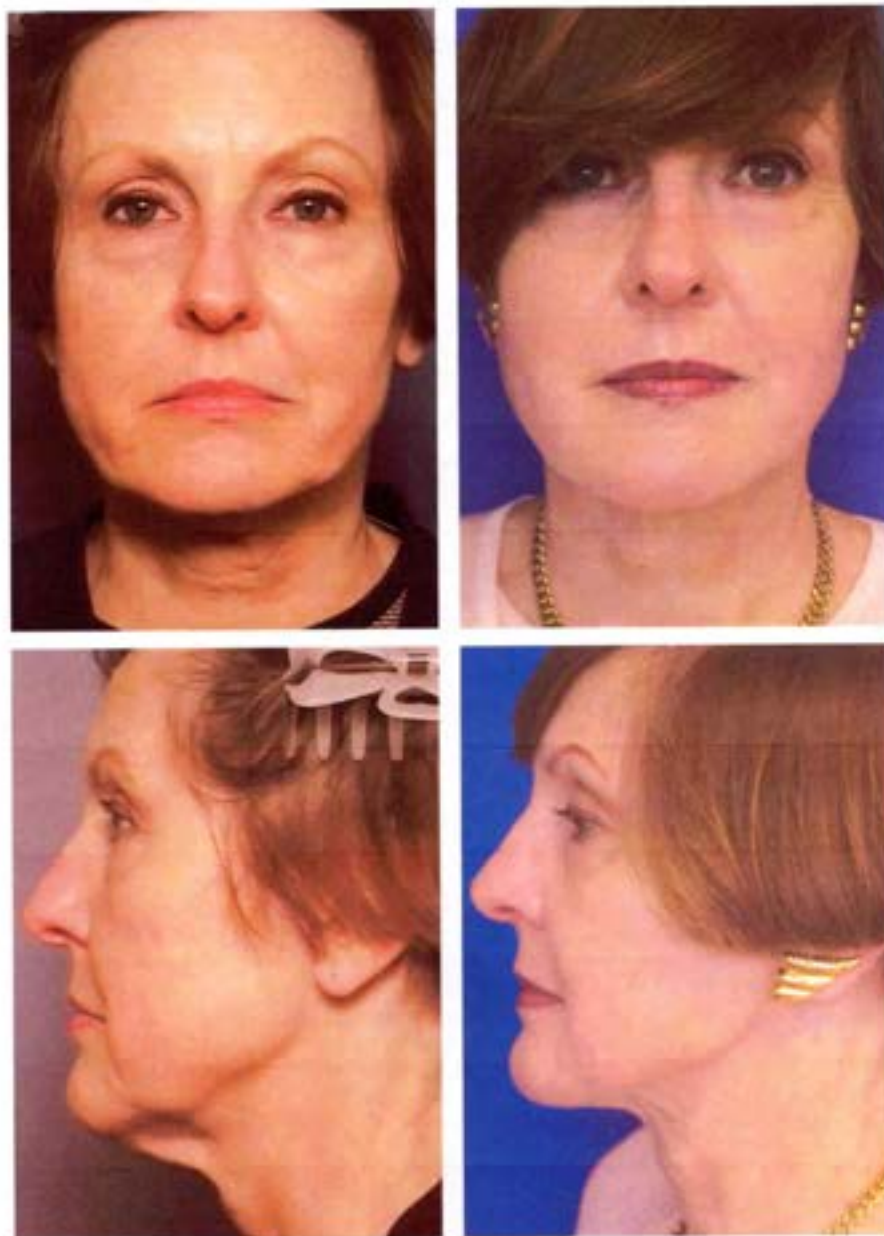

FIG. 6. Case 3. (*Left*) This 59-year-old patient was emotionally averse to the magnitude of a face lift procedure and desired cervical improvement with liposuction alone. She exhibited localized fullness. Despite her age, she demonstrated good snap-back test results, which indicated excellent tone and elasticity, and adequate pinch test results, which excluded the possibility of extreme laxity. (*Right*) One year after suction-assisted lipectomy and perioral laser treatment, all five Ellenbogen-Karlin criteria were met.

proved jowl contours. The cephalic portion of the jowl was never suctioned superficially; the cannula was always positioned well below the

dermis. The smallest available cannula was used for the jowls. Feathering and fine-tuning with a 1.8-mm or 2-mm Mercedes cannula, with

FIG. 5. Case 2. (*Left*) This 53-year-old patient insisted that she could not afford a face lift. She demonstrated localized fullness, which is the best predictor of a good outcome (even better than age or skin tone). There was no crepe paper appearance (the best predictor of failure) to her skin. (*Center*) Four months postoperatively, Ellenbogen-Karlin criteria 1, 4, and 5 were met. Although an acceptable result was obtained, criteria 2 (visible subhyoid depression) and 3 (visible thyroid cartilage bulge) were not met. (*Right*) Five years postoperatively, the patient still looked better than she did preoperatively. The color change along the jawline, resulting from the CO₂ laser treatment, should be noted.

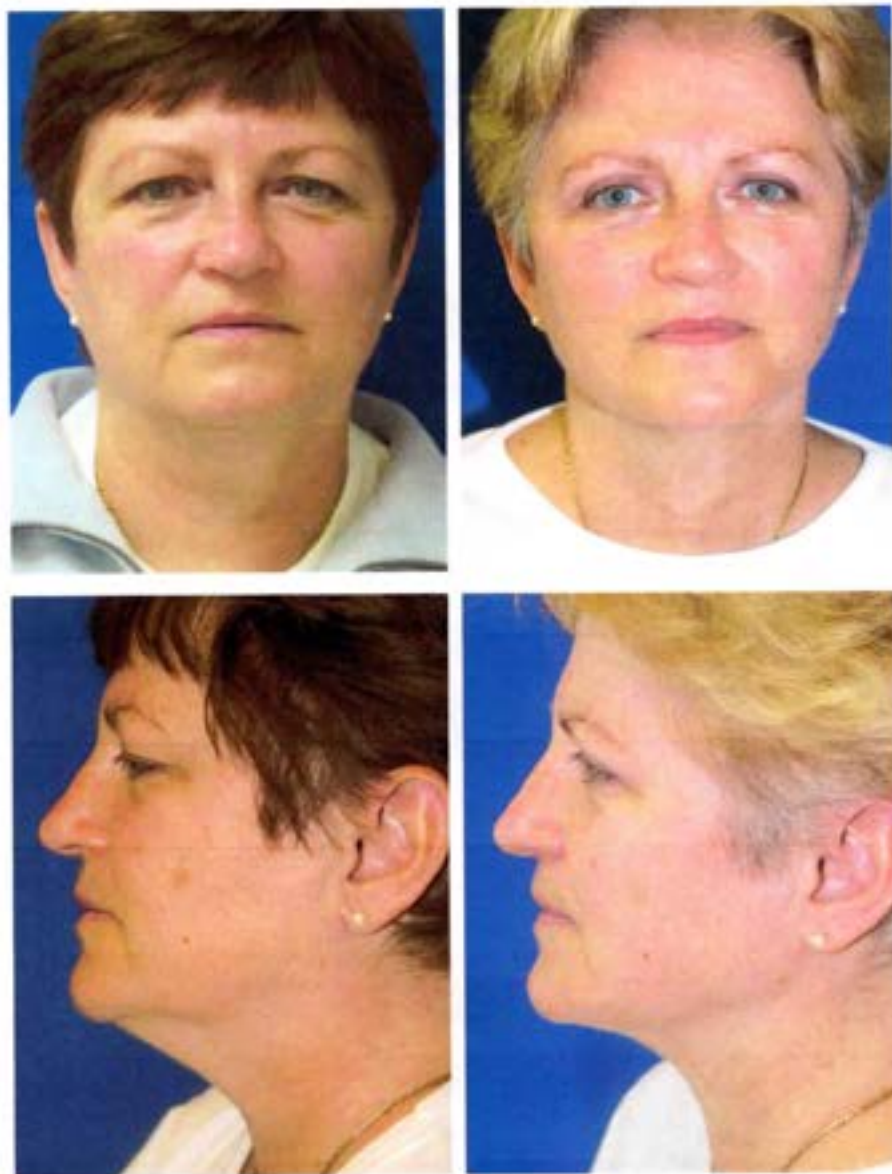

FIG. 7. Case 4. (*Left*) This 58-year-old patient did not think she could afford the recovery time for a face lift. (*Right*) One year postoperatively, all five Ellenbogen-Karlin criteria were met.

or without suction, was performed. Lipoinfiltration (lipotransfer) was used to fill any resulting irregularities.

Endpoints included serial palpation results and visible improvement. A pinch-and-roll test was used to confirm uniform thickness.²⁶ The cannula was swept externally along the skin surface, to confirm a smooth contour. The patient was placed intraoperatively in the sitting position for a final assessment.

At the completion of suction-assisted lipectomy, even upward traction was applied to the skin. Topifoam (3 M, St. Paul, Minn.) was applied while the skin was kept smooth. Smooth

stable compression with the foam and a chin strap is of paramount importance, because displacement or malpositioning may trap edema, causing persistent, troublesome, unsightly irregularities. The head was kept upright without cervical flexion for 1 week, to prevent formation of a neck crease. A chin strap was worn 24 hours per day for 1 week and then at night for 6 weeks. A soft diet was recommended for 1 week. At week 2, the patient was instructed to hand-massage firm areas with a circular motion, using vitamin E cream, for 5 to 10 minutes each day. External ultrasound massage was performed by an aesthetician for some patients, as needed.

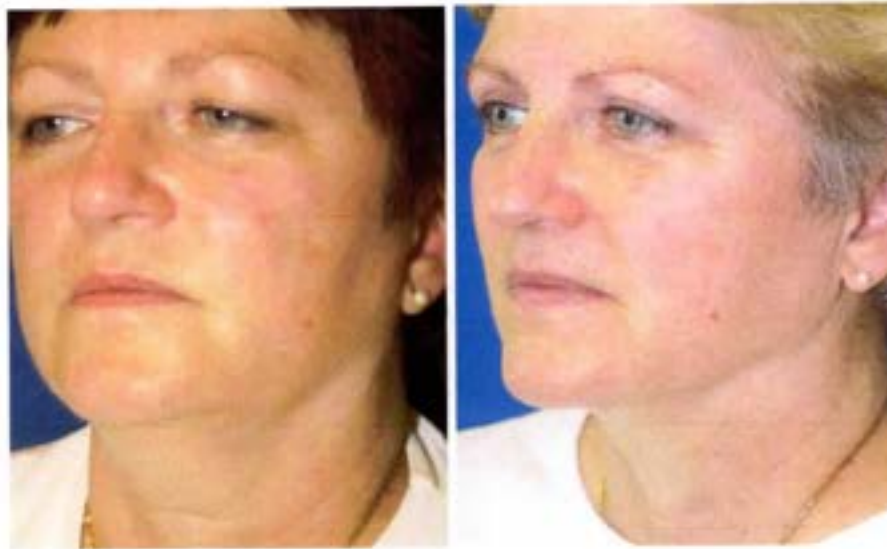

FIG. 8. Case 4. (Left) Before treatment. (Right) One year after treatment.

RESULTS

All patients demonstrated improvements in their aesthetic contours. A good result in this study was defined as satisfying three of the criteria described by Ellenbogen and Karlin,¹⁹ without creating a deformity. The oldest patient considered to demonstrate a good result was a 64-year-old woman. Age 64 seemed to represent a dividing line. Eleven patients were more than 64 years of age. Results for the patients older than 64 years were less satisfactory, often with redundant or crepe paper-like skin. Despite this finding, some of the Ellenbogen-Karlin neck rejuvenation criteria were met for each patient. All patients exhibited an improved submandibular border and a more visible anterior sternocleidomastoid muscle border. All patients demonstrated improved neck angles, as determined with angle measurements. For many patients, all five of the Ellenbogen-Karlin criteria were met. A visible subhyoid depression and a visible thyroid cartilage bulge were the two criteria most often not achieved.

Male patients in this series exhibited fewer irregularities than did women, because of their thicker skin, but demonstrated a comparably less acute cervicomenal angle and less defined jawline. Eight patients (6 percent) required earlobe incisions, which were used early in the series for adequate sculpting of the submandibular border and buccal areas. Earlobe incisions are now rarely necessary. Complications are outlined in Table III.

CASE REPORTS

Case 1: Normal Hyoid, Heavy Neck, Jowling, Platysmal Bands, and Microgenia

This 53-year-old woman was a patient with juvenile-onset, brittle, insulin-dependent diabetes mellitus and a refractory nicotine habit (Figs. 3 and 4). She strongly desired neck and jowl improvement, but I refused to perform a face lift. The patient exhibited localized fullness, with no crepe paper appearance to her skin. Two months after suction-assisted lipectomy, chin implant placement, and upper lid blepharoplasty, she exhibited (1) a distinct inferior mandibular border on frontal view, (2) a subhyoid depression (with a small band), (3) no bulge over the thyroid cartilage, (4) a visible anterior sternocleidomastoid muscle border (providing definition), and (5) a 90-degree sternocleidomastoid-submental line angle. Ellenbogen-Karlin criteria 1, 2, 4, and 5 were met, and criterion 3 (visible thyroid cartilage bulge) was not met.

Case 2: Heavy Neck, Jowling, Adequate Chin Projection, and a Low-Lying Hyoid on Palpation

This 53-year-old patient insisted that she could not afford a face lift (Fig. 5). She desired improvement but did not expect a tight neck. She exhibited localized fullness, which is the best predictor of a good outcome (even better than age or skin tone). There was no crepe paper appearance (the best predictor of failure) to her skin. Four months after suction-assisted lipectomy and facial laser treatment, the patient exhibited (1) a distinct inferior mandibular border, (2) an overhang in the subhyoid area resulting from the exposed occult platysmal bands, (3) no bulge over the thyroid cartilage, (4) a visible anterior sternocleidomastoid muscle border (providing definition), and (5) a 90-degree sternocleidomastoid-submental line angle. Ellenbogen-Karlin criteria 1, 4, and 5 were met and, although this represented an acceptable overall result, criteria 2 and 3 were not met.

TABLE IV
Contraindications for Submental Suction-Assisted
Lipectomy

Crepe paper skin appearance
Older patient desiring maximal improvement
Relative contraindications
Severe cervical laxity (Baker type IV)
Multiple deep, permanent, horizontal and oblique creases
Lipectomy alone cannot improve an oblique angle between chin and neck, unless patient has marked subcutaneous fullness

Case 3: Normal Hyoid, Heavy Jowling, Minimal Neck Fullness, and Normal Chin Projection

This 59-year-old patient was emotionally averse to the magnitude of a face lift procedure and desired cervical improvement with liposuction (Fig. 6). She exhibited localized fullness. Despite her age, she demonstrated good snap-back test results, which indicated excellent tone and elasticity, and adequate pinch test results, which excluded the possibility of extreme laxity. One year after suction-assisted lipectomy and perioral laser treatment, all five Ellenbogen-Karlin criteria were met.

Case 4: Normal Hyoid, Heavy Jowling, Heavy Neck, and Normal Chin Projection

This 58-year-old patient desired suction-assisted lipectomy of the neck and did not think that she could afford the recovery time for a face lift (Figs. 7 and 8). She exhibited positive sausage test results, with longitudinal fullness (which I consider to be the best indication for proceeding with suction-assisted lipectomy) evident with midline palpation or squeezing of the submental area. One year after submental suction-assisted lipectomy and upper lid blepharoplasty, all five Ellenbogen-Karlin criteria were met.

DISCUSSION

"Do not let the best destroy the good" describes the principle of choosing suction-assisted lipectomy for patients who are unsuitable candidates for a face lift. For patients with medical contraindications, a face lift can always be performed in the future if their condition improves. Table IV summa-

rizes contraindications, and Table V outlines the advantages and disadvantages of submental suction-assisted lipectomy, as determined in this study.

The principles of submental suction-assisted lipectomy include the following. (1) Correction of a recessive chin as an adjunct to suction-assisted lipectomy helps normalize the appearance of the mandible and neck (4 percent of patients underwent mentoplasty). (2) Suction-assisted lipectomy initiates skin contracture.²⁵ (3) Skin "shrinks" into the cervical concavity. (4) Skin adheres to the underlying tissue. (5) Thicker skin (in particular, the skin of male patients) contracts less. (6) Decreased submental and cervical volume increases skin surface area.

More skin is necessary to fill a concavity, which emphasizes the vertical skin deficiency of patients with a full neck (Fig. 9).¹⁰ Cervical burn scar contractures teach us that additional skin is required for neck contouring. Additional skin is needed to fill the newly created anterior cervical concavity after suction-assisted lipectomy.¹¹ Decreasing the volume of a full neck increases the surface area of the cervicomental angle (the Pythagorean theorem states that the hypotenuse squared is equal to the sum of the other two sides squared).^{19,27} The hypotenuse of the triangle corresponds to the submental length of the full neck preoperatively, but the other two limbs of the triangle contribute to the right angle of the youthful neck. Skin excision is not necessary.²⁸⁻³⁰

Baker³¹ developed a classification system, involving four patient types, for assessment of candidates for short-scar face lifts. Table VI presents my summary of that classification. The four patient types were used to

TABLE V
Advantages and Disadvantages of Suction-Assisted Lipectomy

Advantages	Disadvantages
Less risk for patients with medical problems	Not applicable for older patients with severe cervical and platysma laxity
Less risk of skin slough among smokers	Unightly skin irregularities may result
Less invasive	Secondary platysmaplasty and skin lift may be required
Lower cost	Lipectomy may expose occult or barely visible platysmal bands
Less scarring	Inferior results
Less pain	
Shorter recovery	
Less dissection	
Less risk of nerve injury	
Less risk of hematoma	
Only option for some patients receiving clotting inhibitors	
Shorter procedure and less anesthesia	

retrospectively evaluate outcomes in this series. Baker's classification excludes patients less than 40 years of age. Eighty-eight of 132 patients were more than 40 years of age. This series included 47 patients of Baker type I or II (forties to early fifties; 53 percent of all patients who were >40 years of age). Those patients were observed to be generally good candidates for suction-assisted lipectomy, especially if localized fullness, good tone, and a tight platysma were present. Patients of Baker type III (late fifties to early seventies; 25 percent) could be afforded a benefit if they accepted skin or platysma excess and/or crepe paper-like skin. A visible anterior sternocleidomastoid muscle border and a defined submandibular border could be obtained. Patients of Baker type IV (sixties to seventies; 22 percent) represented the majority of those who were medically unsuitable for a face/neck lift and were willing to accept cervical excess, with irregular contours. However, a distinct jawline and visible anterior sternocleidomastoid muscle border could be sculpted during a shorter procedure than a face lift.

Irregularities or skin adherence to muscle can be avoided with limited skin undermining, careful peripheral dry tunneling and judicious suction-assisted lipectomy with a very small cannula, and lipoinfiltration (if necessary). If the patient desires additional improvement, a full or short-scar face lift with

platysmaplasty is recommended. For correction of residual platysmal bands, botulinum toxin type A injection or surgical correction, with excision of a triangle at the level of the hyoid cartilage and plication, can be performed. Those procedures were not performed in this series.

CONCLUSIONS

There are unusual situations in which older patients with submental fullness may not be candidates for a face lift because of medical contraindications, uncontrolled hypertension, a refractory nicotine habit, or anticoagulant medications or may disqualify themselves because of cost, unavailable recovery time, or emotional resistance to "such a big procedure." Submental suction-assisted lipectomy without platysmaplasty can be helpful for older patients with submental fullness who are unsuitable candidates for a face lift and accept the limitations of suction-assisted lipectomy. During patient selection, consideration must be given to age and excess skin, to avoid a crepe paper appearance, which could require a subsequent face lift for correction.

The results of this 6-year study of 88 patients (40 to 73 years of age), as assessed with the Ellenbogen-Karlin criteria for facial rejuvenation, demonstrate that submental suction-assisted lipectomy, as opposed to a face lift, can be a reasonable alternative even for older patients. A localized fullness area in

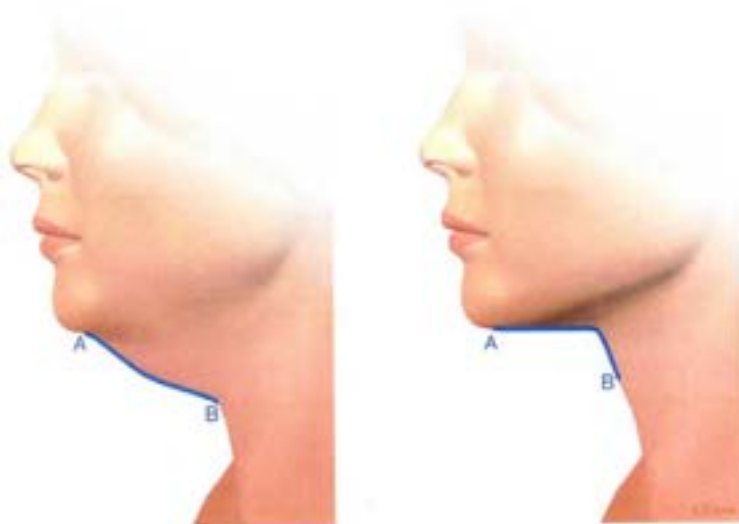


FIG. 9. Diagram indicating that it requires more skin to fill a concavity. Decreasing the volume in a full neck increases the surface area of the cervico-mental angle (i.e., the distances between points A and B are the same) A full neck has too little skin, rather than too much.

TABLE VI
Summary of Baker's Classification of Patient Types for
Short-Scar Face Lifts

	Baker Type			
	I	II	III	IV
Age	40s	Late 40s to 50s	Late 50s to early 70s	60s to 70s
Jowls	Early	Moderate	Significant	Significant
Submental fat	±	+	+	+
Laxity	Slight	Moderate	Moderate	Deep creases
Elasticity	Good	Poor	Poor	Poor

the midline was observed to be the best predictor of a good outcome (even better than age or skin tone). A crepe paper appearance of the skin preoperatively was the best predictor of failure. A mentoplasty seemed to enhance the submental results for patients with a recessive chin.

Suction-assisted lipectomy can sufficiently contract and smooth the skin envelope for older patients in special situations. Consistently good results can be obtained for selected patients in their forties, fifties, or early sixties. The limited results obtained for patients in their late sixties or early seventies in this series were satisfying enough for the patients to avoid or delay a face lift.

Older patients in this series were educated to expect improvement but not a tight neck. Healthy older patients intent on reliable definitive changes were advised to undergo a face/neck lift. Submental suction-assisted lipectomy, which is a shorter procedure than a face lift, was observed to be a reasonable alternative for older patients who were unable or unwilling to undergo a face lift.

Joe M. Gryskiewicz, M.D.

University of Minnesota Academic Health Center
Cleft Palate and Craniofacial Clinics
7373 France Avenue South, Suite 208
Minneapolis, Minn. 55435-4538
grysk001@umn.edu

ACKNOWLEDGMENTS

I thank Paula Hanegraaf Kenow and Melanie Morrison for their help with manuscript preparation.

REFERENCES

1. Tardy, M. E. Lipectomy of the face and neck. In M. E. Tardy, J. R. Thomas, and R. J. Brown (Eds.), *Facial Aesthetic Surgery*. St. Louis, Mo.: Mosby-Year Book, 1995. Pp. 538-542.
2. Thomas, J. R. Facial plastic surgery applications for liposuction. In C. Cummings, J. M. Frederickson, L. A.

- Harker, C. J. Krause, and D. E. Schuller (Eds.), *Otolaryngology-Head and Neck Surgery, Update 1*. St. Louis, Mo.: Mosby-Year Book, 1990. Pp. 160-165.
3. Avelar, J. Fat suction of the submental and submandibular regions. *Aesthetic Plast. Surg.* 9: 257, 1985.
4. Topia, A., Ferreira, B., and Eng, R. Liposuction in cervical rejuvenation. *Aesthetic Plast. Surg.* 11: 95, 1987.
5. Lewis, C. M. Lipoplasty of the neck. *Plast. Reconstr. Surg.* 76: 248, 1985.
6. Singer, R. Improvement of the "young" fatty neck. *Plast. Reconstr. Surg.* 73: 582, 1984.
7. Teimourian, B. Face and neck suction-assisted lipectomy associated with rhytidectomy. *Plast. Reconstr. Surg.* 72: 627, 1983.
8. Pitman, G. H. Fat contouring in the face and neck. *Oper. Tech. Plast. Reconstr. Surg.* 3: 94, 1996.
9. Hugo, N. E. Rhytidectomy and radical lipectomy and platysmal flaps. *Plast. Reconstr. Surg.* 65: 199, 1980.
10. Connell, B. F. Contouring the neck in rhytidectomy by lipectomy and a muscle sling. *Plast. Reconstr. Surg.* 61: 376, 1978.
11. Connell, B. F. Cervical lifts: The value of platysma muscle flaps. *Ann. Plast. Surg.* 1: 34, 1978.
12. Connell, B. F. Neck contour deformities: The art, engineering, anatomic diagnosis, architectural planning, and aesthetics of surgical correction. *Clin. Plast. Surg.* 14: 683, 1987.
13. Guerrero-Santos, J. Surgical correction of the fatty fallen neck. *Ann. Plast. Surg.* 2: 389, 1979.
14. Guerrero-Santos, J., Espallat, L., and Morales, F. Muscular lift in cervical rhytidoplasty. *Plast. Reconstr. Surg.* 54: 127, 1974.
15. Gonzalez-Ulloa, M. Quantitative principles in cosmetic surgery of the face (profile-plasty). *Plast. Reconstr. Surg.* 29: 2, 1962.
16. Powell, N., and Humphreys, B. *Proportions of the Aesthetic Face*. New York: Thieme-Stratton, 1984. Pp. 1-14, 39.
17. Farkas, L. G., and Kolar, J. C. Anthropometrics and art in the aesthetics of women's faces. *Clin. Plast. Surg.* 14: 599, 1987.
18. Ricketts, R. M. Divine proportion in facial aesthetics. *Clin. Plast. Surg.* 9: 401, 1982.
19. Ellenbogen, R., and Karlin, J. V. Visual criteria for success in restoring the youthful neck. *Plast. Reconstr. Surg.* 66: 826, 1980.
20. Tardy, M. E. Aesthetic surgery of the aging neck. In M. E. Tardy, J. R. Thomas, and R. J. Brown (Eds.), *Facial Aesthetic Surgery*. St. Louis, Mo.: Mosby-Year Book, 1995. Pp. 382-400.
21. Vistnes, L. M., and Souther, S. G. The anatomical basis for common cosmetic anterior neck deformities. *Ann. Plast. Surg.* 2: 381, 1979.
22. Marino, H., Galeano, E. J., and Gondolfo, E. A. Plastic correction of double chin: Importance of the position of the hyoid bone. *Plast. Reconstr. Surg.* 27: 544, 1961.
23. Marino, H., Galeano, E. J., and Andolfo, E. A. Plastic correction of double chin: Buenos Aires, Argentina. *Plast. Reconstr. Surg.* 31: 45, 1963.
24. Giampapa, V. C. Suture suspension technique offers predictable, long-lasting neck rejuvenation. *Aesthetic Surg. J.* 20: 253, 2000.
25. Giampapa, V. C. Neck recontouring with suture suspension and liposuction: An alternative for the early rhytidectomy candidate. *Aesthetic Plast. Surg.* 19: 217, 1995.
26. Pitman, G. H. *Liposuction and Aesthetic Surgery*. St. Louis, Mo.: Mosby-Year Book, 1993. Pp. 127-148.